Pancytopenia due to Anaplasmosis

Waqas Jehangir, MD; Elvira Umyarova, MD; Hibba Rehman, MD

The University of Vermont Medical Center, Burlington, VT

Introduction

Anaplasmosis is a tickborne disease caused by the bacterium *Anaplasma phagocytophilum.* Anaplasmosis is transmitted to humans by tick bites. Typical symptoms includes fever, headache, muscle pain, malaise, chills, nausea/abdominal pain, cough, confusion, rash (rare with anaplasmosis) and it varies from person to person. Usually, these symptoms occur within 1-2 weeks of a tick bite.

Case Presentation

- A 78 years old white male with past medical history significant for prostate cancer status post prostatectomy, OSA who was admitted to the hospital for fever and pancytopenia.
- His baseline Hb was 15 which dropped to 10.4, WBC count dropped from 4.06 to 1.57 and platelets dropped from 140 to 33.
- His haptoglobin was <6, LDH was 1435 but peripheral smear did not reveal any schistocytes.
- His coagulation panel revealed prothrombin time 13.9, INR 1.2, PTT 24 and fibrinogen 351, D-dimer was 912 and direct antiglobulin test was negative. His ultrasound abdomen showed splenomegaly.
- He underwent an infectious workup that was negative for RSV, metapneumovirus, influenza A & B, parainfluenza, hepatitis B, hepatitis C, parvovirus infection, and thick smear showed no evidence of parasitic infection.
- His Anaplasma titers were <1:64, and subsequent **PCR for Anaplasma was positive.**
- Patient was started on doxycycline. His most recent counts showed recovery with Hb 13.5, WBCs of 4.39 and platelets of 231.

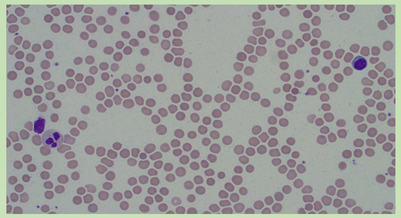

Peripheral smear showing pancytopenia with thrombocytopenia

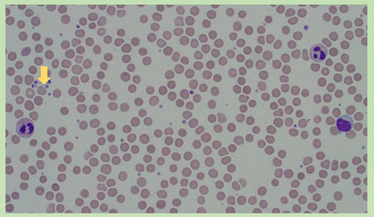

Peripheral smear showing improved cytopenias with increased platelets

Discussion

Anaplasmosis is most frequently reported from the upper Midwestern and northeastern of US. New York, Connecticut, New Jersey, Rhode Island, Minnesota, and Wisconsin accounts for 90% of all reported cases.

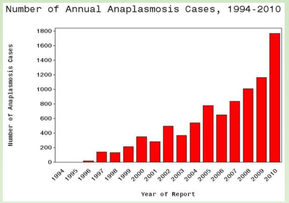

The number of cases reported to CDC has increased steadily from 2000 to 2010.

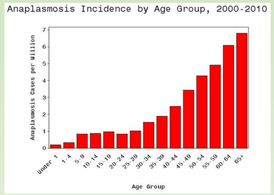

CDC data also shows an increasing trend with age.

"Anaplasmosis can be a serious illness that can be fatal if not treated correctly, even in previously healthy people.

It can be difficult to diagnose given it can mimic Lyme's disease or rocky spotted mountain fever, and other infections.

Diagnostic tests based on the detection of antibodies frequently appear negative and a PCR can confirm the diagnosis. Once diagnosis is suspected, patient should be treated with doxycycline. The unusual aspect of this case is hemolysis. Normally, leukopenia and thrombocytopenia is see with anaplasmosis, however, hemolysis is mostly seen with babesiosis."

Conclusion

This case focuses on the importance of thinking outside the box of hematologic causes of pancytopenia especially with increasing numbers of reported cases.

Reference

The Centers for Disease Control and Prevention. Anaplasmosis statistics and epidemiology. http://www.cdc.gov/anaplasmosis/stats/index.html (Accessed on October 21, 2017).